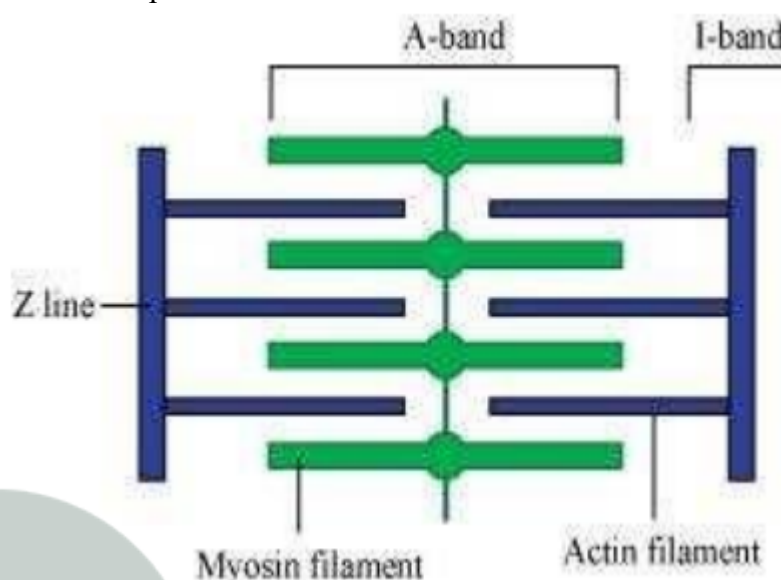


# NCERT Solutions for Class-XI Biology

## Chapter-20

1. Draw the diagram of a sarcomere of skeletal muscle showing different regions.
1. The diagrammatic representation of a sarcomere is as follows:



2. Define sliding filament theory of muscle contraction.
2. According to sliding filament theory of muscle contraction, the actin and myosin filaments slide past each other with the help of cross-bridges to reduce the length of the sarcomeres.
3. Describe the important steps in muscle contraction.
3. During skeletal muscle contraction, the thick filament slides over the thin filament by a repeated binding and releases myosin along the filament. This whole process occurs in a sequential manner.

Step 1: Muscle contraction is initiated by signals that travel along the axon and reach the neuromuscular junction or motor end plate. Neuromuscular junction is a junction between a neuron and the sarcolemma of the muscle fibre. As a result, Acetylcholine (a neurotransmitter) is released into the synaptic cleft by generating an action potential in sarcolemma.

Step 2: The generation of this action potential releases calcium ions from the sarcoplasmic reticulum in the sarcoplasm.

Step 3: The increased calcium ions in the sarcoplasm leads to the activation of actin sites. Calcium ions bind to the troponin on actin filaments and remove the tropomyosin, wrapped around actin filaments. Hence, active actin sites are exposed and this allows myosin heads to attach to this site.

Step 4: In this stage, the myosin head attaches to the exposed site of actin and forms cross bridges by utilizing energy from ATP hydrolysis. The actin filaments are pulled.

As a result, the H-zone reduces. It is at this stage that the contraction of the muscle occurs.

Step 5: After muscle contraction, the myosin head pulls the actin filament and releases ADP along with inorganic phosphate. ATP molecules bind and detach myosin and the cross bridges are broken.

Stage 6: This process of formation and breaking down of cross bridges continues until there is a drop in the stimulus, which causes an increase in calcium. As a result, the concentration of calcium ions decreases, thereby masking the actin filaments and leading to muscle relaxation.

4. Write true or false. If false change the statement so that it is true.
- (a) Actin is present in thin filament
  - (b) H-zone of striated muscle fibre represents both thick and thin filaments.
  - (c) Human skeleton has 206 bones.
  - (d) There are 11 pairs of ribs in man.
  - (e) Sternum is present on the ventral side of the body.
4. (a) True
- (b) False – H-Zone of striated muscle fibres represents only thick filaments.
- (c) True
- (d) False – There are 12 pairs of ribs in man.
- (e) True

5. Write the difference between:

- (a) Actin and Myosin
- (b) Red and White muscles
- (c) Pectoral and Pelvic girdle

5. (a) Actin and Myosin

Actin		Myosin	
1.	Actin is a thin contractile protein.	1.	Myosin is a thick contractile protein.
2.	It is present in light bands and is called an isotropic band.	2.	It is present in dark bands and is called an anisotropic band.

(b) Red and White muscles

Red muscle fibre		White muscle fibre	
1.	Red muscle fibres are thin and smaller in size.	1.	White muscle fibres are thick and larger in size.
2.	They are red in colour as they contain large amounts of myoglobin.	2.	They are white in colour as they contain small amounts of myoglobin
3.	They contain numerous mitochondria.	3.	They contain less number of mitochondria.
4.	They carry out slow and sustained contractions for a long period.	4.	They carry out fast work for short duration.
5.	They provide energy by aerobic respiration.	5.	They provide energy by anaerobic respiration.

(c) Pectoral and Pelvic girdle

Pectoral girdle	Pelvic girdle
-----------------	---------------

1.	It is a skeletal support from where the forelimbs of vertebrates are attached.	1.	It is a skeletal support form where the hind limbs of vertebrates are attached.
2.	It is composed of two Bones namely, clavicle or collar bones and scapula or shoulder bone.	2.	It is composed of three bones, upper ileum, inner pubic, and ischium.

6. Match Column I with Column II:

Column I		Column II	
(a)	Smooth muscle	(i)	Myoglobin
(b)	Tropomyosin	(ii)	Thin filament
(c)	Red muscle	(iii)	Sutures
(d)	Skull	(iv)	Involuntary

6.

Column I		Column II	
(a)	Smooth muscle	(iv)	Involuntary
(b)	Tropomyosin	(ii)	Thin filament
(c)	Red muscle	(i)	Myoglobin
(d)	Skull	(iii)	Sutures

7. What are the different types of movements exhibited by the cells of human body?

7. Movement is a characteristic feature of living organisms. The different types of movement exhibited by cells of the human body are:

- Amoeboid movement: Leucocytes present in the blood show amoeboid movement. During tissue damage, these blood cells move from the circulatory system towards the injury site to initiate an immune response.
- Ciliary movement: Reproductive cells such as sperms and ova show ciliary movement. The passage of ova through the fallopian tube towards the uterus is facilitated by this movement.
- Muscular movement: Muscle cells show muscular movement.

8. How do you distinguish between a skeletal muscle and a cardiac muscle?

8. The differences between skeletal muscles and cardiac muscles are as follows:

Skeletal muscle	Cardiac muscle
The function of skeletal muscles is voluntary.	The function of Cardiac muscles involuntarily.
The cells of these muscles are unbranched.	The cells of these muscles are branched.
Intercalated discs between the cells are absent.	Intercalated discs between the cells are present
They help in locomotory actions and body posture	Cardiac muscles help in working the heart

9. Name the type of joint between the following:

- (a) atlas/axis
- (b) carpal/metacarpal of thumb
- (c) between phalanges
- (d) femur/acetabulum
- (e) between cranial bones
- (f) between pubic bones in the pelvic girdle

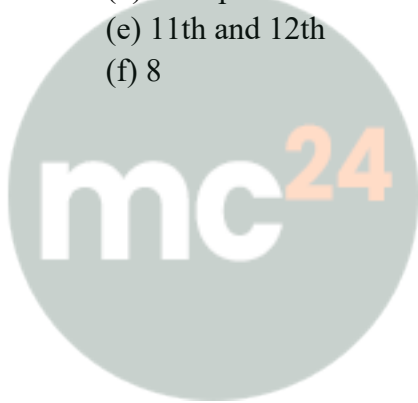
9. (a) atlas/axis: Pivotal joint

- (b) carpal/metacarpal of thumb: Saddle joint
- (c) between phalanges: Hinge joint
- (d) femur/acetabulum: Ball and socket joint
- (e) between cranial bones: Fibrous joint
- (f) between pubic bones in the pelvic girdle: Ball and socket joint

**10.** Fill in the blank spaces:

- (a) All mammals (except a few) have \_\_\_\_\_ cervical vertebra.
- (b) The number of phalanges in each limb of human is \_\_\_\_\_
- (c) Thin filament of myofibril contains 2 'F' actins and two other proteins namely \_\_\_\_\_ and \_\_\_\_\_.
- (d) In a muscle fibre  $\text{Ca}^{++}$  is stored in \_\_\_\_\_
- (e) \_\_\_\_\_ and \_\_\_\_\_ pairs of ribs are called floating ribs.
- (f) The human cranium is made of \_\_\_\_\_ bones.

- 10.**
- (a) 7
  - (b) 14
  - (c) tropomyosin, troponin
  - (d) sarcoplasmic reticulum
  - (e) 11th and 12th
  - (f) 8



**Myclass24**  
Your Class. Your Pace.